

**INTRATHECAL ANAESTHESIA WITH TUNNELLING FOR POSTOPERATIVE PAIN RELIEF**

Swati Sujeer, Ravi Madhusudhana\*, Sujatha M P ,Bhavana B G.

Department of anaesthesiology, Sri Devaraj urs medical college, kolar, karnataka  
Swati Sujeer, Resident Post Graduate, Anaesthesiology, Sri Devaraj Urs Medical College, Kolar, Karnataka.

Ravi Madhusudhana, Professor, Anaesthesiology, Sri Devaraj Urs Medical College, Kolar, Karnataka.

Sujatha M P, Assistant Professor, Anaesthesiology, Sri Devaraj Urs Medical College, Kolar, Karnataka.

Bhavana B G, Resident Post Graduate, Anaesthesiology, Sri Devaraj Urs Medical College, Kolar, Karnataka.

**\*Corresponding Author:**

Prof.Ravi Madhusudhana,Dept of Anaesthesiology, Sri Devaraj Urs Medical College, Kolar, Karnataka.ravijaggu@gmail.com

**Abstract**

Perioperative pain relief in cancer patients can be with oral opioids, injectable opioids and Regional blocks with catheters for prolonged pain relief. Requirements of medications are more as the disease progresses and they may come to us for pain relief or associated comorbid conditions due to involvement of other organ systems that may require surgical intervention. We are reporting a case which came for a urological procedure and we went ahead with a Tunneling procedure for prolonged pain relief.

**Key Words:** Post operative Pain, Sub-Arachnoid block, Tunneling.

**Introduction**

Pain may be defined as an unpleasant sensory or emotional experience associated with actual or potential tissue damage. Chronic pain is defined as pain still present after three months despite appropriate treatment. Generally, patients with poor pain control despite comprehensive medical management may be treated with neuraxial

techniques such as continuous epidural or spinal anesthetic. The benefits from intrathecal drug administration include; better pain control, lesser doses of analgesic requirement and fewer unwanted side effects. Catheter fixation is a very important part of the process. Its outward migration might lead to loss of analgesia and unsuccessful attempts to re-establish it.

Many factors have been correlated with migration, but a good fixation technique for the catheter should be the most practical way to prevent it. Subcutaneous tunnelling offers good fixation. This fixation is more acceptable to patients when lying flat. An adhesive dressing over the catheter seals both the catheter entry points and decreases chances of catheter contamination or infection.

### Case Report

A 50 year old lady was admitted with carcinoma cervix stage IIIB with bleeding per vaginum and anuria since 3 days. This was associated with intractable pain abdomen radiating to the back. She was operated for obstructive uropathy 4 months prior with Double J stenting under spinal anaesthesia. Her routine blood investigations revealed blood urea: 48 mg/dl, Serum creatinine: 2.1 mg/dl, Hemoglobin: 9.3 gm/dl, WBC: 10,490 cells/dl and other investigations were normal. An abdomino-pelvic USG was performed which revealed an ill defined heterogenous lesion in lower segment of uterus with increased vascularity. It also showed a large cystic lesion 8X6.5 cms in right adnexa; ovarian in origin. The kidneys were normal in size with increased cortical echogenicity and mild to moderate hydronephrosis was seen. A urine routine was performed which revealed epithelial cells and WBC minimally. An MRI of pelvis was done which revealed a cervical mass with extension to upper 1/3<sup>rd</sup> of vagina, bilateral parametrial invasion and bilateral distal ureteral involvement, FIGO stage IIIB. It also revealed the presence of a complex ovarian cyst on the right adnexa of the uterus. A plan for Double J stenting for her

obstructive symptoms was planned. The requirement of post operative analgesia in view of her condition was also considered. Initially, the plan was for us to perform the procedure and a combined spinal – epidural combination. But, during the procedure, owing to technical difficulties and inadvertent dural puncture; the procedure was converted to that of a continuous spinal using the same 20G catheter. It was secured using tunneling technique to be maintained for 10 days. Subcutaneous tunneling was done using epidural needle up to the side of chest and a loop was fixed with proline. (Fig 1,2) Intraoperative anaesthesia was provided with 2 ml of 0.5% bupivacaine heavy injected intrathecally. The level of anaesthesia was obtained till T<sub>6</sub> and was deemed adequate. Following the procedure, patient was kept in the recovery room till her first dose of rescue analgesia was required. The rescue analgesia was provided in the form of 100 micrograms of buprenorphine diluted to a concentration of 50 microgram/cc and was injected via the catheter intrathecally. Patient was assessed for pain relief; following which she was shifted to post operative ward.

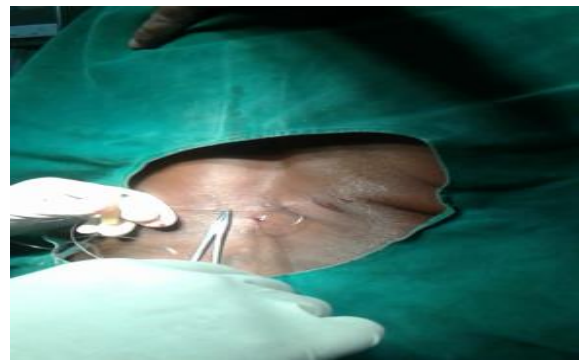


Fig 1: showing the loop and Fixation of Catheter.

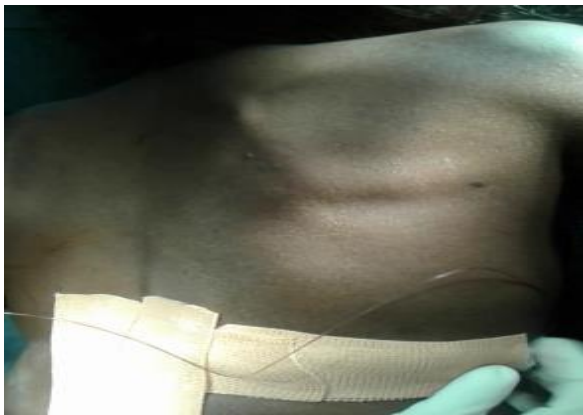

Fig 2: Showing Final fixation of Catheter to side of chest.

Patient had pain free period of 10-12 hours following the top-up. The VAS scores were 2 after the Top up. The top up was repeated every 10-12 hours to a max dosage of not more than 200 micrograms/24 hours. She was able to ambulate well and carry on her routine activities. The catheter fixation site was checked for any signs of inflammation or infection. Everyday dressing was done with betadine ointment. The catheter was removed on the 11th postoperative day of insertion and was sent for culture. It was deemed free of any pathogens after 3 days.

### Discussion

A catheter is a thin plastic tube that is inserted into the subarachnoid or epidural space that bathes the nerves of the spinal cord. Any analgesics can be given through this tube by a pump to act on the nerves carrying pain. [1] To position the catheter, one end is placed through the skin, piercing the superficial structures then finally the intrathecal space in the interspinous region of spine. The other end is threaded (tunnelled) under the skin and is usually brought out through the skin over the front

of the lower ribs. This helps to reduce the risk of infection and to make the fixation of the catheter more secure. Leaving a loop of catheter on the skin during tunnelling is normally a strategy to prevent dislodgement of the catheter. [2] An interposed loop reduces the outwardly traction on the catheter, dampens any drag on the catheter, thus protecting the part of the catheter entering the intrathecal space. Intrathecal catheter based anaesthesia and analgesia techniques went into disrepute a few years back due to the occurrence of cauda equina syndrome in several patients. A report by Rigler and Drasner et al submitted in the year 1991 showed a series of six cases of cauda equina syndrome occurring in patients where continuous spinal was performed using micro catheters sizes ranging from 28-30G. The significant point which differed in our case was that we never made use of any micro catheters thereby avoiding the complications that could have arisen as a result of it. [3] With micro catheters, the occurrence of cauda equina syndrome was associated with the fact that higher doses of local anaesthetic was used in view of achievement of adequate anaesthetic level and the micro catheter also delivered higher concentration of the drug to the base of the various spinal nerves thereby reaching higher toxicity levels in these zones. The use of intrathecal macro catheters also showed higher incidences of PDPH especially in parturients which was not observed in this case. [4] Various studies have concluded that tunnelling decreases the incidence of migration but does not abolish it. [2] Apart from catheter migration, factors such as individual pain threshold and

complexity of surgical procedure contribute toward failure of analgesia. Tripathi and Pandey conducted a study for an epidural catheter which showed a high incidence (29%) of local inflammation at the site of tunnelling. [2] It was not so in our present case scenario. The use of epidural analgesia for postoperative period or in prolonged analgesia as required in oncological patients is widespread. This was a case scenario where an intrathecal catheter was tunneled for postoperative analgesia as well as providing chronic pain relief for oncological pain with stable hemodynamics. The migration of catheter is the main reason for suboptimal analgesia, and secure fixation is required to prevent catheter dislodgement. The technique should also be operator friendly and comfortable to the patient.

### Conclusion

The above exercise in pain relief provides us an insight into the possible use of intrathecal catheter to deliver adequate analgesia for pain relief in intractable chronic pain without causing any extraneous infections. The tunneling of the intrathecal catheter was another novel method to secure the catheter in situ and prevent its migration and displacement.

### References

1. Burton, A. W., Rajagopal, A., Shah, H. N., Mendoza, T., Cleeland, C., Hassenbusch, S. J. and Arens, J. F. (2004), Epidural and Intrathecal Analgesia Is Effective in Treating Refractory Cancer Pain. *Pain Medicine*, 5: 239–247. Tripathi M, Pandey M. Epidural catheter fixation: Subcutaneous tunnelling with a loop to prevent displacement. *Anaesthesia* 2000; 55:1113-6.
2. Rigler, Mark L. MD; Drasner, Kenneth MD; Krejcie, Tom C. MD; Yelich, Sharon J. MD; Scholnick, Faith T. DO; DeFontes, James MD; Bohner, David CRNA. Cauda Equina Syndrome After Continuous Spinal Anesthesia. *Anesth analg* 1991;72:275-81.
3. Horlocker, Terese T. MD; McGregor, Diana G. MBBS; Matsushige, Derek K. MD; Chantigian, Robert C. MD; Schroeder, Darrell R. MS; Besse, Jennifer A. BA. Neurologic Complications of 603 Consecutive Continuous Spinal Anesthetics Using Macrocatheter and Microcatheter Techniques. *Anesth Analg* 1997;84:1063-70.
4. Burstal R, Wegener F, Hayes C, Lantry G. Subcutaneous tunnelling of epidural catheters for postoperative analgesia to prevent accidental dislodgement: A randomized controlled trial. *Anaesth Intensive Care* 1998;26:147-51.