

Research Paper

Open Access

ANAESTHETIC MANAGEMENT OF A PATIENT WITH SEVERE THORACO LUMBAR KYPHOSCOLIOSIS POSTED FOR EMERGENCY INCISION AND DRAINAGE OF PERIANAL ABSCESS.**THREJA .C. K, NIKHILA .R, SUPRIYA.T C, RAVI .M, DINESH .K**

Assistant Professor, Dept of Anaesthesiology, Sri Devaraj Urs Medical College, Kolar, Karnataka
Resident Postgraduate, Dept of Anaesthesiology, Sri Devaraj Urs Medical College, Kolar, Karnataka

Resident Postgraduate, Dept of Anaesthesiology, Sri Devaraj Urs Medical College, Kolar, Karnataka

Professor, Dept of Anaesthesiology, Sri Devaraj Urs Medical College, Kolar, Karnataka
Professor & HOD, Dept of Anaesthesiology, Sri Devaraj Urs Medical College, Kolar, Karnataka

Abstract

Use of regional anaesthesia in patients with severe kyphoscoliosis is a dilemma and controversial. Severe kyphoscoliosis patients are associated with functional and physical problems which are posing a challenge in planning the technique and management of anaesthesia. Here we present a case of severe kyphoscoliosis successfully managed under spinal anaesthesia.

Key Words: kyphoscoliosis, sub arachnoid block.

Introduction:

Kyphoscoliosis is due to the disruption of balance between structural and dynamic components or the neuromuscular elements of the spine [1]. It is due to forward and lateral bending in spine and rotation of the vertebrae as well as a deformity of the rib cage [2]. It could be due to tuberculosis in developing countries. The severity is best determined by measuring Cobb's angle [3]. Greater Cobb's angle, more profound the disturbance in pulmonary function. Patients with angle $>90^\circ$ may develop marked ventilatory abnormality [4]. There could be usually secondary involvement of the respiratory, cardiovascular and neurologic

systems [5]. Airway management and cardio respiratory disturbances make general anaesthesia complicated where as regional anaesthesia is associated with technical problems due to abnormal curvature of spine and unpredictability of the level of anaesthesia. Thus a careful pre-anaesthetic evaluation and optimization should be done.

Case report:

A 45 year old male patient presented with perianal abscess with deformity of thoracolumbar kyphoscoliosis posted for emergency surgery for incision and drainage. Patient gave history of pain and swelling in perianal region for a week. On pre anaesthetic evaluation patient was

conscious, co-operative, oriented, moderately built and nourished. His pulse was 74/min, BP118/60 mmHg and on examination patient had swelling in perianal region with pain in the perineum and mild fever. Airway was Mallampatti grade 2. He had severe thoracolumbar Kyphoscoliosis (Fig.1). Patient had no significant history of any medical illness like tuberculosis or polio.

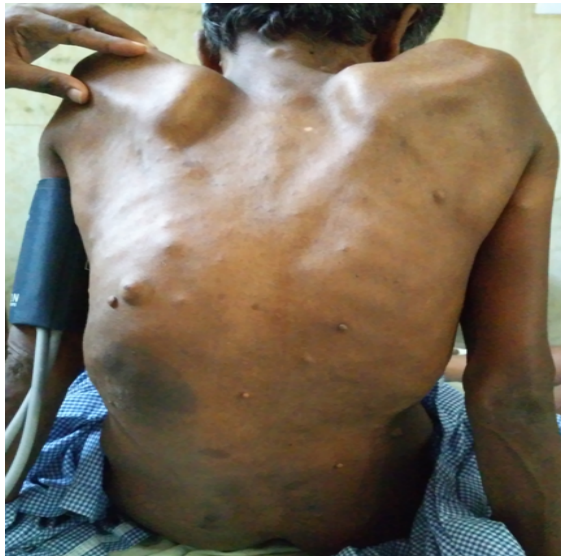

Fig 1: Showing the spine with deformity

Investigations revealed hemoglobin 13.5g% bleeding time 2min 40 sec & clotting time 5 min 30 sec, platelet count 1.45 lakh/mm³, Blood urea 21mg/dl, serum creatinine 0.47 mg/dl, sodium 133 meq/l potassium 4.8meq/l all within normal limits. Total leucocyte count was raised. ECG was within normal limits, X-ray chest not done, X-ray spine exaggerated scoliotic deformity of the lumbar spine note with exaggerated kyphosis of thoracic spine (Fig.2). Since the patient was posted for emergency surgery

further evaluation of patient was not done.

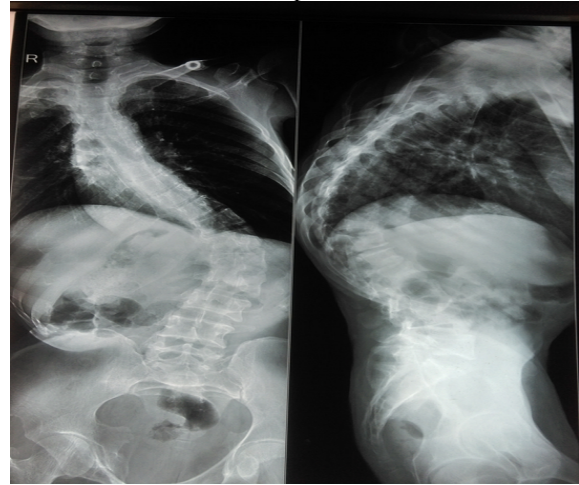


Fig 2: X ray Spine showing Scoliosis and Kyphosis

The risks of anaesthetic technique, difficult spinal anaesthesia and complications like partial block, failed spinal, high spinal; general anaesthesia and post-operative intensive care were explained to patient and his care taker and the patient was accepted for anaesthesia under ASA grade 3 'E' physical status with written informed consent.

Patient was shifted to the operation theatre and intravenous access was obtained with 18G IV cannula, patient was preloaded with 500 mL Ringer lactate. Patient was connected to pulse oximeter, NIBP and ECG monitors. Difficult intubation cart was kept ready. Patient was prepared for sub arachnoid block. As there was severe thoraco lumbar kyphoscoliosis palpation of the spine was found very difficult. Space was identified by tracing the spine from upwards and the patient was administered spinal anaesthesia by median approach at L2- L3 space in sitting position after 2 attempts with injection bupivacaine heavy 0.5 % 1.3 ml with 25 microgm of fentanyl- 0.5 ml was given with 25G spinal needle and patient was made to sit for 15 mins. Analgesia was achieved in the sacral area. Spinal anaesthesia related hypotension was also kept in mind, so the limit on the

total dose of the drug and correct positioning was done to achieve adequate level of blockade. Oxygen was administered through the Hudson mask throughout the surgery. Hemodynamic parameters & saturation were monitored and maintained within normal limits, duration of sensory block lasted for 94min. Patient was monitored and shifted toward later uneventfully.

Discussion:

Kyphoscoliosis can produce restrictive type of respiratory disorder [2]. The severity of pulmonary problem can be correlated with the angle of the deformity [4]. Weinstein and colleagues reported that Cobb's angle above 60 degrees results in progressive pulmonary and cardiac failure [6]. Harrison et al reported that pulmonary impairments are most notable at kyphosis angles >55 degrees [7]. Preoperative assessment should focus on cardiovascular, respiratory or neurological impairment related to the deformity. In patients with curves >60°, cardiologic evaluation to assess ventricular size and pulmonary hypertension is required [8]. Spinal anaesthesia could be the option in certain cases of kyphoscoliosis with severe restrictive lung disease and there are case reports of successful spinal blockade in such patients [9]. The main disadvantage of regional anaesthesia could be decreased success rate due to difficulty in palpation of inter vertebral space, unsuccessful insertion, multiple attempts before successful insertion, failed or inadequate blockade [10]. Distortion of the spinous process and rotation of the vertebral column can make identification of the intervertebral space difficult in these patients [11]. In difficult cases spinal needle insertion through lumbosacral space and sacral foramina have been reported with increased incidence of successful puncture [12]. With a normal coagulation and profile subarachnoid block is a good alternative [13]. Severe kyphoscoliosis can be associated with

decrease in the volume of CSF, with hypobaric technique or with rapid injection a higher than expected level can occur, hyperbaric bupivacaine provides safe and consistent block. In our patient block was uniform and symmetrical.

Conclusion

A detailed preanaesthetic assessment and optimisation of respiratory and cardiovascular system is imperative. Properly planning of the block and meticulous approach will result in successful outcome in severe kyphoscoliosis.

Reference:

- [1] Korula S, Ipe S, Saramma SP. Parturient with severe kyphoscoliosis: An anesthetic challenge. *J Obstet Anaesth Crit Care* 2011;1:81-4.
- [2] Horlocker TT, Wedel DJ. Anesthesia for orthopedic surgery, Chapter 40, in *Clinical Anesthesia* by Barash PG, Cullen BF, Stoelting RK eds. Fifth ed. Lippincott Williams and Wilkins 2005-2.
- [3] Tuli SM. Tuberculosis of the spine. New Delhi: Amerind Publishing Co; 1975-3.
- [4] Levine DB. Scoliosis. *Curr Opin Rheumatol* 1990; 2:190-5.
- [5] Anand kulk. *Indian Journal of Anaesthesia* 2007; 51 (6) : 486-495
- [6] Weinstein SL, Zavala DC, Ponseti IV. Idiopathic scoliosis long term follow up and prognosis in untreated patients. *J Bone Joint Am* 1981; 63:702-12.
- [7] Harrison RA1, Siminoski K, Vethanayagam D, Majumdar SR. Osteoporosis-related kyphoscoliosis and impairment in pulmonary function: a systematic review. *J Bone Miner RES.* 2007; 22(3):447-57.
- [8] Gupta S, Singaria G. Kyphoscoliosis and pregnancy. *Indian J Anaesth* 2004;48:215-20
- [9] Saraswath, M., Radhakrishnan, M.. Spinal Anesthesia In A Patient With Kyphoscoliosis *ISPUB* 2001.6;1.
- [10] Gurayten ozyurt, Elif Basagan-Mogol Hulya Bilgin, Oguz Tokat. *Tohoku. Spinal*

Anesthesia in a patient with severe thoracolumbar Kyphoscoliosis. *J Exp Med* 2005; 207:239-242.

- [11] Ko JY, Leffert LR. Clinical implications of neuraxial anaesthesia in the parturient with scoliosis. *Anesth Analg* 2009; 109:1930-4.
- [12] Taylor JA. Lumbosacral subarachnoid tap. *J Urol.* 1940; 43:561.
- [13] Dinesh K, Ravi M, Ramesh Kumar PB, Krishna Kumar BR, Kishore KS, Somasekharam P. Severe thoraco lumbar kyphoscoliosis- a challenge to anaesthesiologists. *Int J Pharm Biomed Res* 2012; 3(1):69-70.